

## Integrated Use of Transthoracic Ultrasound and Echocardiography in Evaluating Patients with Chronic Obstructive Pulmonary Disease

Ahmed Gouda El Gazzar<sup>1</sup>, Tarek Samy Essawy<sup>1</sup>,

Hany Hassan Ebaid<sup>2</sup>, Asmaa El Desoukey Mohammad<sup>\*1</sup>, Shaimaa Magdy AboYoussof<sup>1</sup>

Departments of <sup>1</sup>Chest and <sup>2</sup>Cardiology, Faculty of Medicine, Benha University, Benha, Egypt

\*Corresponding author: Asmaa El Desoukey Mohammad, Mobile: (+20) 01095408871, E-Mail: dr.asmaa3030@gmail.com

### ABSTRACT

**Background:** Multiorgan clinical ultrasonography (pulmonary, cardiac, and vascular) has emerged as a tool of considerable usefulness in managing patients with chronic obstructive pulmonary disease (COPD) in numerous situations, including detecting concomitant heart failure or associated pulmonary hypertension.

**Objective:** To study the role of integrated use of transthoracic ultrasound and echocardiography in evaluating patients with COPD and their relation to the severity of the disease.

**Patients and Methods:** This study included 100 patients with clinically stable COPD during their follow up in the Chest Department and Chest Outpatient Clinic, Benha University Hospital. Patients were divided and classified according to GOLD 2019 (based on post bronchodilator FEV1) into 4 groups, each consisted of 25 patients.

**Results:** All COPD patients in this study, were males, with a mean age of  $60.77 \pm 6.05$  years (49–73). Prominent A lines were detected in 69% of patients, irregular pleural line was present in 12% of patients and A profile was detected in 43% of patients. The diaphragmatic ultrasound (US) findings were significantly decreased with the increase of severity. 86% of the study patients showed abnormal echo findings. Severe TR was recorded in 23% and severe PH was recorded in 5%. LVDD grade I was recorded in 33% of patients and LVDD grade II was reported in 7%. LVSD was reported in 4% of patients and cor pulmonale was reported in 12% of them.

**Conclusion:** Integrated use of transthoracic US and echocardiography is of great usefulness in evaluating COPD patients, screening for PH, estimating the prognosis, and in careful monitoring of these patients.

**Keywords:** COPD, Echocardiography, Spirometry, Transthoracic Ultrasound.

### INTRODUCTION

A common, preventable, and treatable condition known as chronic obstructive pulmonary disease (COPD) is characterised by recurrent respiratory symptoms and airflow restriction brought on by abnormalities in the airways and/or alveoli, which are typically brought on by prolonged exposure to noxious particles or gases <sup>(1)</sup>.

The most frequent extrapulmonary symptoms in COPD patients are cardiac signs. Pulmonary hypertension, cor pulmonale, right ventricular dysfunction, and left ventricular dysfunction are all caused by COPD's effects on the pulmonary blood arteries, right ventricle, and left ventricle <sup>(2)</sup>.

To assess the right ventricular function, right ventricular filling pressure, tricuspid regurgitation, left ventricular function, and valve functions, echocardiography offers a quick, noninvasive, portable, and nearly accurate approach <sup>(3)</sup>.

Transthoracic ultrasound (TTUS) is portable, reproducible, nonionizing, and independent of particular acoustic windows, making it suited for a thorough examination in a variety of settings, including inpatient and outpatient, in both acute and chronic diseases <sup>(4)</sup>.

Numerous studies have been conducted to analyse individuals with COPD and distinguish them from those

with other similar illnesses using ultrasonography to measure diaphragmatic function, air trapping, and A lines <sup>(5)</sup>.

The aim of this work was to study the role of integrated use of transthoracic ultrasound and echocardiography in evaluating patients with chronic obstructive pulmonary disease and their relation to the severity of the disease.

### PATIENTS AND METHODS

This study was carried out on 100 patients with clinically stable chronic obstructive pulmonary disease (COPD) during their follow up in the Chest Department and Chest Outpatient Clinic, Benha University Hospital.

#### Inclusion criteria:

100 patients with stable COPD (Diagnosis and severity of COPD was done according to the Global Initiative for Chronic Obstructive Lung Disease guidelines 2019) <sup>(6)</sup>. COPD patients included in the study were all diagnosed by clinical examination together with spirometry (post bronchodilator forced expiratory volume in the first second (FEV1)/Forced vital capacity (FVC) <70%).

**They were divided into 4 groups according to post bronchodilator FEV<sub>1</sub> into <sup>(6)</sup>:**

- **Group 1** included 25 patients with COPD stage 1 (mild): post bronchodilator FEV<sub>1</sub> ≥ 80% predicted.
- **Group 2** included 25 patients with COPD stage 2 (moderate): post bronchodilator 50% ≤ FEV<sub>1</sub> < 80% predicted.
- **Group 3** included 25 patients with COPD stage 3 (severe): post bronchodilator 30% ≤ FEV<sub>1</sub> < 50% predicted.
- **Group 4** included 25 patients with COPD stage 4 (very severe): post bronchodilator FEV<sub>1</sub> < 30% predicted.

**Exclusion criteria:**

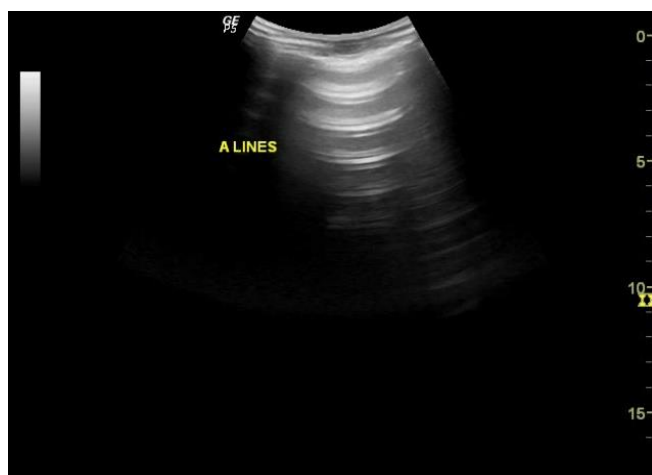
Patients with chronic lung disease other than COPD, primary cardiac disease (history of congenital, rheumatic heart diseases), any systemic disease that can cause pulmonary hypertension (e.g., collagen vascular diseases), patients with poor echo window, and patients who were unable to perform spirometry.

**All patients were subjected to the following:**

- Full history taking, complete physical examination (General and local).
- Pulmonary function tests (spirometry).
- Plain chest X-ray, CT chest (when needed).
- Arterial blood gases analysis.
- Laboratory investigations (e.g., KFTs, LFTs, CBC, ESR), ECG.
- Transthoracic Ultrasound (TTUS).
- Echocardiography.

**Transthoracic Ultrasonography (TTUS):**

All cases were examined by **TTUS** using both low-frequency convex and high frequency linear transducers for lung and pleura examination to detect the regularity of the pleural lines and the prominence of the A lines. Ultrasonographic chest examination was done using B-mode, time-motion mode (M-mode) (Fig. 1).



**Fig. (1):** Multiple prominent A lines

**The following US findings were assessed:**

Lung sliding, artifact types and lung profiles, any abnormal sonographic findings (consolidation, pneumothorax, pleural effusion), assessment of diaphragm: measure diaphragmatic thickness, and movement of the diaphragm using B mode and M mode.

**Ultrasonography of the diaphragm:**

- Patients were examined in semi-recumbent position. Right hemi diaphragm was evaluated by B-mode and M-mode ultrasound as it was easily visualized through the large acoustic window of the liver, while visualization of the left diaphragm was more difficult because of the smaller window of the spleen, so we chose to examine the right one.
- Diaphragmatic thickness (TD) was measured at zone of apposition at different lung volumes and capacities (Fig. 2).
- Diaphragmatic excursion was assessed using B and M mode with the lower frequency curvilinear probe placed subcostally parallel to the intercostal space between the midclavicular and anterior axillary lines, “anterior subcostal view”.

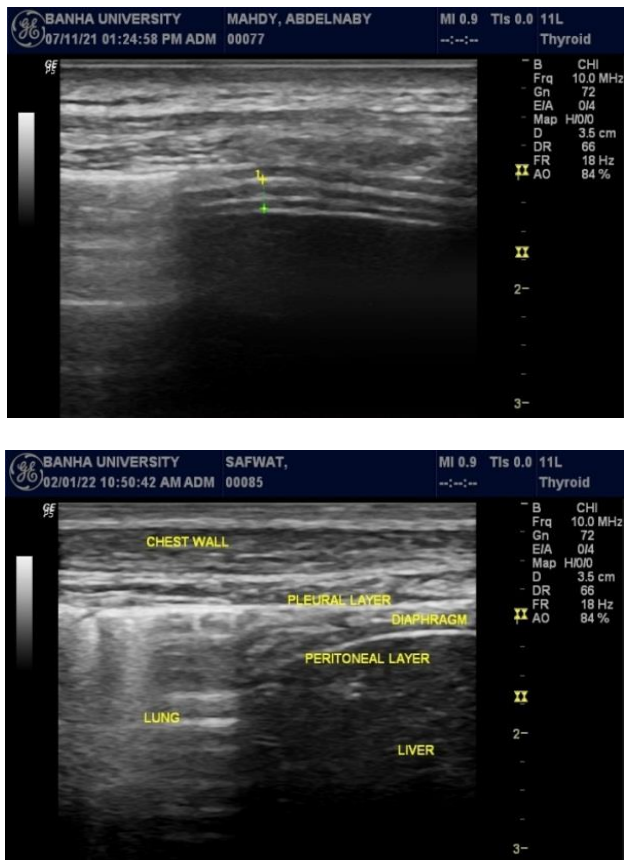
- **Echocardiography examination:** All patients were subjected to conventional transthoracic echocardiography (TTE) and tissue Doppler imaging (TDI), and the following parameters were assessed: **Assessment of the left side of the heart:** Left ventricular dimensions (LVDD and LVDs), LV systolic function and diastolic function.

- M mode and two-dimensional techniques were used to assess **left ventricular ejection fraction and dimension techniques** in short-axis and long-axis left parasternal views.

- **Peak velocity of early diastolic flow (E), peak velocity of atrial contraction (A), and their ratio (E/A),** were measured over the mitral valve in apical four chamber view, and were used to evaluate left ventricular diastolic function. Also, they were evaluated by **Tissue Doppler imaging** (Ea, Aa on lateral and septal mitral valve) measured in the lateral mitral annulus at early diastole (Ea), in septal mitral annulus during late diastole (Aa), and their ratio [Ea/Aa(m)].

- **Assessment of the right side of the heart:** Right ventricular (RV) size, **Tricuspid Annular Plane Systolic Excursion (TAPSE)** (was assessed with M-mode (M-mode probe placed on the free wall angle of the tricuspid valve) in apical four-chamber view to assess **RV systolic function**), Tricuspid and pulmonary valvular evaluation (Tricuspid regurgitant flow, tricuspid regurgitant velocity (TRV) and systolic pulmonary artery pressure).

- Color flow Doppler technique and continuous wave Doppler were used to identify **tricuspid regurgitation flow** and for measurement of the **maximum jet velocity**.



**Fig. (2):** Measurement of diaphragm thickness at zone of apposition in B mode. The diaphragm is imaged as a

structure with three distinct layers, including two parallel echoic lines (the diaphragmatic pleura and the peritoneal membrane) and a hypoechoic structure between them (the muscle itself).

**Ethical consent:**

An approval of the study was obtained from Benha University Academic and Ethical Committee. Every patient signed an informed written consent for acceptance of participation in the study. This work has been carried out in accordance with The Code of Ethics of the World Medical Association (Declaration of Helsinki) for studies involving humans.

**Statistical analysis**

The collected data were coded, processed and analyzed using the SPSS (Statistical Package for the Social Sciences) version 22 for Windows® (IBM SPSS Inc, Chicago, IL, USA). Data were tested for normal distribution using the Shapiro Wilk test. Qualitative data were represented as frequencies and relative percentages. Quantitative data were expressed as mean ± SD (Standard deviation) and range. One-way ANOVA test was used to compare between the groups of normally distributed variables (parametric data). P value < 0.05 was considered significant.

**RESULTS**

All COPD patients in this study, were males, with mean age of 60.77 ± 6.05 years. 84% of them were current smokers. 13% were hypertensive. The mean BMI in the studied patients was 25.32 ± 2.57, ranges from 19 to 31 kg/m<sup>2</sup>. There were significant differences between the four groups regarding BMI (Table 1).

**Table (1): Demographic characteristics of all patients (n=100)**

Variable		Frequency (n=100)
Age (years) Mean ± SD (range)		60.77 ± 6.05 (49-73)
BMI (Kg/m <sup>2</sup> ) Mean ± SD (range)		25.32 ± 2.57 (19-31)
		<b>No. (%)</b>
Sex	Male	100 (100%)
	Female	0 (0%)
Smoking	Current Smoker	84 (84%)
	Ex-smoker	16 (16%)
Comorbidities	Absent	76 (76%)
	DM	4 (4%)
	HTN	13 (13%)
	DM+HTN	7 (7%)

The spirometric parameters (FEV1/FVC% post BD, FVC%, Post BD FEV1%, MVV% and PaO<sub>2</sub>) were significantly decreased with the increase of severity (Table 2).

**Table (2): Spirometric parameters of the study groups (n=100)**

Variable	Mild group (n=25)	Moderate group (n=25)	Severe group (n=25)	Very severe group (n=25)	Test	P value
	Mean ± SD	Mean ± SD	Mean ± SD	Mean ± SD		
FEV1/FVC% Post BD	68.19±1.04	59.02±4.56	42.12±2.15	27.72±1.58	F= 1113	<0.001
FVC%	93.86±2.32	83.98±3.75	78.12±4.21	72.64±4.45	F= 144	<0.001
Post BD FEV1%	81.32±1.03	61.92±4.7	41.5±2.81	25.98±1.5	F= 1747	<0.001
MVV%	72.68±2.79	56.45±5.2	38.34±2.06	35.1±2.8	F= 649	<0.001
PaO <sub>2</sub> mmHg	85.44±2.62	80.88±1.54	74.68±2.59	72±1.96	F= 279	<0.001

Prominent A lines were detected in 69% of patients, irregular pleural line was present in 12% of patients. A profile was detected in 43% of patients (Table 3).

**Table (3): US findings among the study patients (n = 100)**

Variable		Frequency (n=100)
		No. (%)
A lines	Prominent	69 (69%)
	Non-prominent	31 (31%)
Pleural line	Regular	88 (88%)
	Irregular	12 (12%)
Parenchyma	Abnormality detected	0 (0%)
	No abnormality detected	100 (100%)
Profile	A profile	43 (43%)
	Non	57 (57%)

The diaphragmatic US findings among the study patients are shown in table 4.

**Table (4): Diaphragmatic US findings among the study patients (n = 100)**

Variable		Statistics (n=100)
		Mean ± SD (range)
Thickness	TD RV (mm)	2.94±0.405 (1.99 – 3.74)
	TD FRC (mm)	3.402±0.384 (2.4 – 4.1)
	TD TLC (mm)	5.16±0.78 (3.3 – 6.5)
Thickness fraction (TF)		0.757±0.139 (0.375 – 1.261)
Excursion (cm)		3.925±0.561 (2.79 – 4.92)

All the diaphragmatic ultrasound findings were significantly decreased with the increase of severity (Tables 5).

**Table (5): Diaphragmatic US findings among the study patients groups (n = 100)**

Variable		Mild group (n=25)	Moderate group (n=25)	Severe group (n=25)	Very severe group (n=25)	Test	P value
		Mean ± SD	Mean ± SD	Mean ± SD	Mean ± SD		
Thickness	TD RV (mm)	3.33±0.169	3.21±0.134	2.83±0.169	2.39±0.193	F=160	<0.001
	TD FRC (mm)	3.82±0.134	3.59±0.115	3.31±0.197	2.88±0.179	F=159	<0.001
	TD TLC (mm)	6.04±0.314	5.54±0.201	4.99±0.152	4.08±0.366	F=236	<0.001
Thickness fraction (TF)		0.816±0.116	0.726±0.064	0.768±0.107	0.719±0.209	F=2.72	0.048
Excursion (cm)		4.59±0.224	4.15±0.234	3.76±0.144	3.2±0.29	F=166	<0.001

86% of the study patients showed abnormal echo findings. Severe TR was recorded in 23% and severe PH recorded in 5%. LVDD grade I was recorded in 33% of patients. LVSD was reported in 4% of patients and

cor pulmonale was reported in 12% of them. Abnormal TAPSE (<1.6) was detected in 3% of patients (Table 6).

**Table (6): Echo findings conclusion among the study patients (n = 100)**

Variable		Frequency (n=100)
		No. (%)
<b>Echo normality</b>	Normal echo	14 (14%)
	Abnormal echo	86 (86%)
<b>TR</b>	No TR	16 (16%)
	Mild TR	23 (23%)
	Moderate TR	38 (38%)
	Severe TR	23 (23%)
<b>PH</b>	No PH	29 (29%)
	Mild PH	17 (117%)
	Moderate PH	49 (49%)
	Severe PH	5 (5%)
<b>LVDD</b>	No LVDD	60 (60%)
	LVDD grade I	33 (33%)
	LVDD grade II	7 (7%)
<b>LVSD</b>	LVSD -ve	96 (96%)
	LVSD +ve	4 (4%)
<b>Cor pulmonale</b>	Cor pulmonale -ve	88 (88%)
	Cor pulmonale +ve	12 (12%)
<b>TAPSE</b>	Normal (>1.6)	97 (97%)
	Abnormal (<1.6)	3 (3%)

There was highly significant positive correlation between PH degree and TR degree and severity degree of COPD where increase severity degrees of PH and TR were associated with increased severity of COPD (Table 7).

**Table (7): Correlation between LVDD, LVSD, TR, PH and severity degree of COPD**

Variable \ Severity degrees of COPD	Spearman's Correlation Coefficient (rho)	P
<b>LVDD</b>	- 0.061	0.55
<b>LVSD</b>	0.228*	<b>0.022</b>
<b>PH degree</b>	0.824**	<b>&lt;0.001</b>
<b>TR degree</b>	0.771**	<b>&lt;0.001</b>

There was highly significant inverse correlation between spirometric parameters (FEV1, FVC, FEV1/FVC) and LVEDD, LVESD and TAPSE. There was statistically significant positive correlation between FEV1, FVC, FEV1/FVC and A1. There was significant positive correlation between FEV1/FVC and EF%. There was significant inverse correlation between spirometric parameters (FEV1, FVC, FEV1/FVC) and Ea medial mitral cm/sec and between spirometric parameters (FEV<sub>1</sub> and FEV1/FVC) and Aa medial mitral cm/sec (Table 8).

**Table (8): Correlation some echo findings (LVEDD, LVESD, EF, E<sub>1</sub>, A<sub>1</sub>, E/A<sub>1</sub>, SPAP, Ea and Aa mitral, TAPSE,) and spirometric results in COPD patients (FEV<sub>1</sub>, FVC, FEV<sub>1</sub>/FVC)**

Parameter	FEV <sub>1</sub>		FVC		FEV <sub>1</sub> /FVC	
	r	P	r	P	r	P
LVEDD mm	-0.460	<0.001	-0.434	<0.001	-0.430	<0.001
LVESD mm	-0.399	<0.001	-0.412	<0.001	-0.373	<0.001
EF%	0.181	0.072	0.124	0.22	0.209	<b>0.037</b>
E <sub>1</sub> (early mitral inflow velocity)	0.132	0.191	0.141	0.163	0.105	0.299
A <sub>1</sub> (late mitral inflow velocity)	0.322	<b>0.001</b>	0.222	<b>0.027</b>	0.339	<b>0.001</b>
E/A <sub>1</sub>	-0.072	0.476	-0.008	0.94	-0.105	0.301
Ea lateral mitral cm/sec	0.008	0.937	0.059	0.558	-0.029	0.776
Ea medial mitral cm/sec	-0.244	<b>0.014</b>	-0.214	<b>0.033</b>	-0.253	<b>0.011</b>
Aa lateral mitral cm/sec	0.108	0.284	0.134	0.184	0.078	0.441
Aa medial mitral cm/sec	-0.199	<b>0.047</b>	-0.114	0.258	-0.240	<b>0.016</b>
TAPSE cm	-0.363	<0.001	-0.330	<b>0.001</b>	-0.352	<0.001

r: Correlation coefficient

## DISCUSSION

In managing patients with COPD, multiorgan clinical ultrasonography (pulmonary, cardiac, and vascular) has become a tool that is extremely helpful in a variety of situations, such as the differential diagnosis of dyspnea of uncertain origin, the assessment of the etiology in episodes of exacerbation, detecting concurrent heart failure or associated pulmonary hypertension<sup>(7)</sup>.

A prevalent and significant cause of death during and after a COPD exacerbation is cardiovascular disease<sup>(8)</sup>. To assess the right ventricular function, right ventricular filling pressure, tricuspid regurgitation, left ventricular function, and valve functions, echocardiography offers a quick, noninvasive, portable, and nearly accurate approach<sup>(3)</sup>.

This study included 100 patients with clinically stable chronic obstructive pulmonary disease (COPD) during their follow up in the Chest Department and Chest Outpatient Clinic, Benha University Hospital. Patients were divided and classified according to GOLD 2019 (based on post bronchodilator FEV<sub>1</sub>) into 4 groups each consisted of 25 patients<sup>(6)</sup>.

In this study, All COPD patients were males, with age ranging from 49 to 73 years with a mean of 60.77 ± 6.05 years. 84% of them were current smokers and 16% were ex-smokers. Thirteen percent were hypertensive, 4% were diabetics and 7% were both diabetics and hypertensive. The mean BMI in the studied patients was 25.32 ± 2.57, ranged from 19 to 31 kg/m<sup>2</sup>.

This study showed male sex predominance, and this might be directly related to smoking habits,

occupational, and outdoor air pollution exposure among males as compared to females. This was in accordance with **El Wahsh et al.**<sup>(9)</sup> whose study included 30 male (83.3%) and 6 female patients (16.7%), also with **Kumar et al.**<sup>(10)</sup> who found that majority of COPD patients (82.72%) were males. Also, in agreement with **Abd El-hay et al.**<sup>(11)</sup> who showed male majority among COPD patients in their study.

This study showed that the spirometric parameters (FEV<sub>1</sub>/FVC%, FVC%, FEV<sub>1</sub>%, MVV% of predicted, and PaO<sub>2</sub>) significantly decrease with the increase of severity of COPD. These results are in agreement with that done by **Abd El Aziz et al.**<sup>(12)</sup> who showed that FEV<sub>1</sub>% of predicted, FEV<sub>1</sub>/FVC, and MVV% of predicted varied among the four subgroups of patients with COPD with the least results in very severe COPD group.

In the current study all cases were examined by transthoracic ultrasound (pleural, lung and diaphragmatic US examinations) and by transthoracic echocardiography for cardiac evaluation. This study showed that prominent A lines was detected in 69% of patients, irregular pleural line was present in 12% of patients. No patients showed parenchymal abnormality and A profile detected in 43% of patients.

A lines, seen in normal lungs, may be more prominent in COPD lungs. Prominent A lines were detected in 69% of COPD patients in this study. These results are in agreement with that done by **Abou Youssuf et al.**<sup>(13)</sup> who detected prominent A lines in 60% of the studied COPD patients. Also, with **Lichtenstein and Meziere**<sup>(14)</sup> who showed that prominent A lines plus lung sliding indicated

obstructive lung disease with 89% sensitivity and 97% specificity.

Regarding diaphragmatic US this study showed that among the study patients the mean TD RV was  $2.94 \pm 0.405$  mm, the mean TD FRC was  $3.402 \pm 0.384$  mm, the mean TD TLC was  $5.16 \pm 0.78$  mm. The thickness fraction (TF) was  $0.757 \pm 0.139$  and the excursion was  $3.925 \pm 0.561$  cm, and these findings were significantly decreased with the increase of severity. These results are in agreement with that done by **Abd El Aziz et al.** <sup>(12)</sup> who found that TD changed according to lung volumes and increased as the lung volume increased from RV to TLC.

In the current study we integrated the use of transthoracic echocardiography with transthoracic US for cardiac evaluation in the studied COPD patients and correlated findings with COPD severity. All patients were examined by two-dimensional transthoracic conventional, M mode and Doppler echocardiography and by tissue Doppler imaging (TDI) for evaluation of the right and left sides of the heart.

This study showed that 14% of the studied COPD patients had normal echo and 85% had abnormal echo (in 52% of mild group, 92% of moderate group and in all patients with severe and very severe grades of COPD). These results are in agreement with that done by **Kumar et al.** <sup>(10)</sup> whose study was conducted on 110 COPD patients and showed that 86% of patients had abnormal echocardiographic findings. On the other hand, **Gupta et al.** <sup>(2)</sup> detected normal echo in 50% of patients (20/40) in their study.

In the present study tricuspid regurgitation was present in about 84% of the patients with variable degrees from mild to severe. TAPSE was normal in 97% patients. PH was found in 71% of patients (71/100) in which prevalence of mild, moderate, and severe PH were 17%, 49%, and 5%, respectively. The frequencies of PH in mild, moderate, severe, and very severe COPD were 8%, 19%, 100%, and 100%, respectively. Most of the patients (49%) who developed PH had moderate degree of PH (50–70 mmHg). In this study it is also observed that severe PH was present only in severe or very severe COPD. 12 patients (12%) had cor pulmonale.

There was highly significant positive correlation between PH degree and TR degree and severity degree of COPD where increased severity degrees of PH and TR were associated with increased severity of COPD. These results are in agreement with **Gupta and Mann** <sup>(15)</sup> whose study was conducted on 100 COPD patients and showed that tricuspid regurgitation (TR) was observed in 67.5% of cases. Pulmonary hypertension (PH) was observed in 63% of cases in which prevalence of mild, moderate, and severe PH were 58.82%, 23.53%, and 17.65%, respectively. The frequencies of PH in mild, moderate, severe, and very severe COPD were 16.67%, 54.55%, 60.00%, and 83.33%, respectively. The study also showed a good

correlation between the frequency of PH and severity of COPD disease.

The results in this study also agreed with **Mohammed et al.** <sup>(16)</sup> who used echocardiography to evaluate cardiac function in 60 patients with stable COPD and showed that tricuspid regurge was found in ~75%, with variable grades from mild to severe, with positive correlation between grades of obstruction and tricuspid regurge. TAPSE was normal in all patients.

The results in this study are also in accordance with **Gupta et al.** <sup>(2)</sup> who showed that severe PH is present in severe or very severe COPD and the incidence of PH is directly proportional to severity of disease.

European Society of Cardiology (ESC) and the European Respiratory Society (ERS) (ERS/ESC) guidelines for PH recommend cardiac ultrasound as a screening method for detecting PH in patients with COPD. This method could be useful in the estimation of the prognosis and in careful monitoring of these patients with increased morbidity. The definitive diagnostic of pulmonary hypertension relies on right heart catheterization (RHC), the “gold standard” method for PH diagnosis <sup>(17)</sup>.

Correlation between pulmonary functions and echocardiography findings in the current study revealed a statistically significant positive correlation between FEV1/FVC and EF% and late mitral inflow velocity [A]. There was highly significant inverse correlation between spirometric parameters (FEV1, FVC, FEV1/FVC) and LVEDD, LVESD and TAPSE. There was significant inverse correlation between spirometric parameters (FEV1, FVC, FEV1/FVC) and Ea medial mitral cm/sec and Aa medial mitral cm/sec.

The results in this study also are in accordance with **Rajput et al.** <sup>(18)</sup> who used echocardiography to evaluate 50 Patients with chronic obstructive pulmonary disease and its relation with the severity of the disease and found a positive correlation between FEV1, FVC, FEV1/FVC [%] and ejection fraction [EF] (FVC had negative correlation with EF), early mitral inflow velocity [E], late mitral inflow velocity [A], E/A ratio, tricuspid regurgitant velocity [TR], mitral annular velocity during late diastole [Aa(m)] and a negative correlation with right ventricular systolic pressure [RVSP], mitral annular velocity during early diastole [Ea(m)], mitral annular velocity during early diastole to mitral annular velocity during late diastole ratio [Ea/Aa(m)].

## CONCLUSION

Integrated use of transthoracic US and echocardiography is of great usefulness in evaluating COPD patients, screening for PH, estimating the prognosis, and in careful monitoring of these patients.

**Conflict of interest:** The authors declare no conflict of interest.

**Sources of funding:** This research did not receive any specific grant from funding agencies in the public, commercial, or not-for-profit sectors.

**Author contribution:** Authors contributed equally in the study.

## REFERENCES

1. **Global initiative for Chronic Obstructive Lung Disease (2021):** Global strategy for the diagnosis, management, and prevention of chronic obstructive pulmonary disease. Global Initiative for Chronic Obstructive Lung Disease, Pp. 1-13 <https://goldcopd.org/2022-gold-reports-2/>
2. **Gupta N, Agrawal R, Srivastav A et al. (2011):** Echocardiographic evaluation of heart in chronic obstructive pulmonary disease patient and its co-relation with the severity of disease. Lung India: Official Organ of Indian Chest Society, 28(2): 105-109.
3. **Daniels L, Krummen D, Blanchard D (2004):** Echocardiography in pulmonary vascular disease. Cardiology Clinics, 22(3): 383-399.
4. **Volpicelli G (2013):** Lung sonography. J Ultrasound Med., 32(1): 165-171.
5. **Wu T (2014):** Ultrasound, an issue of critical care clinics. Crit Care Clin., 300:1-84.
6. **Singh D, Agusti A, Anzueto A et al. (2019):** Global Strategy for the Diagnosis, Management, and Prevention of Chronic Obstructive Lung Disease: the GOLD science committee report 2019. Eur Respir J., 53(5):1900164.
7. **Macho J, de Casasola G, García F (2020):** Clinical ultrasonography in chronic obstructive pulmonary disease. Revista Clínica Española (English Edition), 220(3): 190-196.
8. **Chung L, Winship P, Phung S et al. (2010):** Five-year outcome in COPD patients after their first episode of acute exacerbation treated with non-invasive ventilation. Respiriology, 15(7): 1084-1091.
9. **El Wahsh R, Ahmed M, Yaseen R (2013):** Evaluation of left ventricular function in patients with chronic obstructive pulmonary disease with or without pulmonary hypertension. Egyptian Journal of Chest Diseases and Tuberculosis, 62(4):575-582.
10. **Kumar H, Verma A, Pandey A et al. (2020):** Echocardiographic evaluation of stable chronic obstructive pulmonary disease (COPD): patients. J Assoc Chest Physicians, 8(2):88-91.
11. **Abd El-hay A, Abd Elnaby H, El-gamal M (2019):** Ultrasonographic assessment of diaphragmatic function and its correlation with chronic obstructive pulmonary disease severity. The Egyptian Journal of Hospital Medicine, 76(7): 4524-4532.
12. **Abd El Aziz A, El Wahsh R, Abd Elaal G et al. (2019):** Ultrasonographic assessment of diaphragm in patients with chronic obstructive pulmonary disease in correlation with spirometric parameters. Menoufia Medical Journal, 32(1): 198-203.
13. **Abou Youssuf H, Abdelnabi E, Abd El Hafeez A et al. (2016):** Role of transthoracic ultrasound in evaluating patients with chronic obstructive pulmonary disease. Egyptian Journal of Bronchology, 10(3): 274-282.
14. **Lichtenstein D, Meziere G (2008):** Relevance of lung ultrasound in the diagnosis of acute respiratory failure: the BLUE protocol. Chest, 134(1): 117-125.
15. **Gupta R, Mann S (2016):** Correlation between COPD and echocardiographic features with severity of disease. National Journal of Integrated Research in Medicine, 7(1): 26-30.
16. **Mohammed Y, ElShahid G, Osman N et al. (2019):** Cardiac evaluation of patients with chronic obstructive pulmonary disease using echocardiography. Egyptian Journal of Bronchology, 13(1): 12-16.
17. **Gologanu D, Stanescu C, Bogdan M (2012):** Pulmonary hypertension secondary to chronic obstructive pulmonary disease. Romanian Journal of Internal Medicine, 50(4):259-68.
18. **Rajput A, Patil V, Aundhakar S et al. (2016):** Echocardiographic evaluation of patients with chronic obstructive pulmonary disease and its relation with the severity of the disease. Research Journal Of Pharmaceutical Biological and Chemical Sciences, 7 (4): 446-452.